Treatment of minor wounds from dermatologic procedures: A comparison of three topical wound care ointments using a laser wound model

Nathan S. Trookman, MD, FAAD,[a] Ronald L. Rizer, PhD,[b] and Teresa Weber, PhD[c]
Colorado Springs, Colorado, and Wilton, Connecticut

Background: Topical antibiotic ointments are commonly used for postoperative wound care after dermatologic procedures such as curettage, electrodessication, or shave removals. Antibiotics have the potential to cause allergic contact dermatitis and increase drug resistance and may not be necessary for the treatment of clean surgical wounds.

Objective: This study compared the wound healing properties of the topical wound care ointments Aquaphor Healing Ointment (AHO) (Beiersdorf Inc, Wilton, CT), Neosporin (Poly/Bac/Neo) (Johnson & Johnson, New Brunswick, NJ), and Polysporin (Poly/Bac) (Johnson & Johnson) using a laser wound model.

Methods: In this double-blind study, 4 uniform circular erbium/carbon dioxide laser wounds penetrating to the dermis were made in 20 subjects. Each wound was treated 3 times daily for 18 days with AHO, Poly/Bac/Neo, or Poly/Bac, with one wound left untreated (control). Efficacy and safety were assessed using clinical grading, transepidermal water loss, investigator grading of wound appearance, subjective ranking of wound appearance, and adverse event reporting.

Results: Significant improvements in erythema (days 7-18), edema (days 4 and 7), epithelial confluence (days 7-18), and general wound appearance (days 7-18) were observed with AHO compared with Poly/Bac/Neo and Poly/Bac ($P \leq .007$). No differences were observed between Poly/Bac/Neo and Poly/Bac for any clinical parameters. The average transepidermal water loss value on day 4 was significantly less with AHO compared with the other treatments ($P = .0006$). Subjects ranked the treated sites as follows: AHO (best), Poly/Bac, and Poly/Bac/Neo. No adverse events were reported.

Limitations: This was a small pilot study using a laser wound model to replicate minor wounds.

Conclusions: AHO demonstrated fast and effective improvements in several wound healing parameters compared with antibiotic-containing treatments. (J Am Acad Dermatol 2011;64:S8-15.)

Key words: Aquaphor Healing Ointment; laser wound model; Neosporin; Polysporin; postoperative wound care; wound healing.

In 1997, Fleischer et al[1] reported that approximately 25 million procedures that result in a wound to the skin were performed by dermatologists in the United States each year. With the introduction of new techniques and procedures, the proportion of office visits associated with a procedure increased from 29.8% in 1995 to 40.0% in 2001.[1,2] Commonly performed procedures include biopsies,

Abbreviations used:

AHO:	Aquaphor Healing Ointment
CO_2:	carbon dioxide
Poly/Bac:	Polysporin
Poly/Bac/Neo:	Neosporin
TEWL:	transepidermal water loss

From the Colorado Springs Dermatology Clinic PC[a]; Thomas J. Stephens & Associates, Colorado Springs[b]; and Beiersdorf Inc, Wilton.[c]
Publication of this article was supported by Beiersdorf Inc.
Disclosure: Dr Rizer has been a consultant for Johnson & Johnson. Dr Trookman is a consultant for Thomas J. Stephens & Associates. Dr Weber is an employee of Beiersdorf Inc.

Accepted for publication November 1, 2010.
Reprint requests: Teresa Weber, PhD, Beiersdorf Inc, 187 Danbury Rd, Wilton, CT 06897. E-mail: TWeber@bdfusa.com.
Published online January 19, 2011.
0190-9622/$36.00

doi:10.1016/j.jaad.2010.11.011

removal of benign growths such as seborrheic keratoses or actinic keratoses, laser resurfacing, removal of scars and tattoos, phototherapy, and diagnostic procedures,[2] all of which result in a wound affecting the epidermis, dermis, or both. For patients undergoing these procedures, good wound care is important to promote rapid healing and prevent infection.

Current principles for topical wound management are to remove impediments to repair and to maintain an environment conducive to repair.[3] This involves keeping the wound clean and maintaining a moist, insulated, and protected wound surface.[3] Common practice for postoperative wound care is the application of a topical antibiotic-based ointment or white petrolatum, which is then reapplied daily.[4] A dressing is typically applied over the wound for 1 to 2 weeks.[4] Topical antibiotics have been widely accepted as safe and effective for the treatment of these wounds, as they reduce the possibility of infection while also providing a moist environment that promotes wound healing and minimizes the adherence of bandages.[5]

Topical antibiotics commonly used in the United States and Europe include bacitracin, fusidic acid, gentamicin, mupirocin, neomycin sulfate, and polymyxin B sulfate.[4] These antibiotics are frequently used in combination preparations, which provide a broader spectrum of antibacterial coverage. In the United States, Polysporin (Poly/Bac) (polymyxin B sulfate and bacitracin zinc) (Johnson & Johnson, New Brunswick, NJ) and Neosporin (Poly/Bac/Neo) (neomycin sulfate, polymyxin B sulfate, and bacitracin zinc) (Johnson & Johnson) are the most commonly used antibiotic-based ointments.[4,5]

However, overuse of antibiotics has the potential to increase drug resistance. Both mupirocin and neomycin have been reported to cause drug resistance.[5] In addition, the widespread use of topical erythromycin and clindamycin for the treatment of acne has resulted in the appearance of cross-resistant strains of *Propionibacteria*.[6] Resistance rates reported in several European countries have been shown to correlate with the prescribing patterns of dermatologists in their respective country and that these resistant strains of bacteria are likely to be transmissible.[6] In fact, resistant stains of *Propionibacteria* have been found to occur on the skin of the untreated family members who live with antibiotic-treated patients.[6]

Moreover, several topical antibiotics have been shown to cause allergic contact dermatitis, a type IV hypersensitivity reaction that presents acutely as oozing, swollen, and red papules, vesicles, or plaques at the site of contact, which may spread beyond the area of antibiotic contact.[7] Neomycin has been shown to cause allergic contact dermatitis in approximately 11% of patch-tested individuals and in postsurgical populations,[4] whereas bacitracin has been reported to cause allergic contact dermatitis in approximately 8% of patch-tested individuals.[4] In addition, there appears to be a risk of co-reactivity or cosensitivity between these two agents.[4] Allergic contact dermatitis can adversely affect the normal rate of healing in skin wounds.[7]

Smack et al[8] investigated the effect of bacitracin ointment versus white petrolatum in postprocedural wound care. In 922 patients with 1249 wounds, there was no significant difference in infection rates (2% in the petrolatum group vs 0.9% in the bacitracin group; $P = .37$) or healing rates. No patients in the white petrolatum group developed allergic contact dermatitis compared with 4 patients (0.9%) in the bacitracin group. The authors concluded that white petrolatum is a safe and effective wound care ointment with no risk of inducing allergic reactions and with an equally low infection rate compared with bacitracin.[8] In another study of 142 patients, 147 Mohs micrographic surgery wounds on the ear were postoperatively treated with either gentamicin ointment or petrolatum. No significant differences were seen between treatments in the incidence of suppurative chondritis infections (4.76% in the gentamicin group; 6.67% in the petrolatum group), whereas there was a higher incidence of inflammatory chondritis in the gentamicin group (11.90% vs 3.33% for petrolatum). The authors concluded that petrolatum was a less irritating and cost-effective option for wound care in a difficult-to-manage area.[9]

This study compared the wound-healing properties of Aquaphor Healing Ointment (AHO) (Beiersdorf Inc, Wilton, CT), Poly/Bac, and Poly/Bac/Neo. AHO is an over-the-counter skin protectant that contains 41% *US Pharmacopeia* petrolatum, whereas the latter two are over-the-counter first-aid ointments. A laser wound healing model was used to create wounds that were uniform in both depth and diameter to maximize the sensitivity of wound-healing assessments. Wounds were made to the depth of the reticular dermis and were comparable to those created by electrodessication, curettage, or shave removal of lesions. Assessments included both clinical and noninvasive bioinstrumentation measurements and digital photography.

METHODS

Subjects

Men and women aged 25 to 50 years with Fitzpatrick skin type I to III were eligible to be enrolled. Individuals were excluded if they had any known allergy or sensitivity to skin care products or

topical antibiotics or had any disease state or inappropriate physical skin condition that might impair evaluations or increase the individual's health risk. This study was approved by an institutional review board, and each study participant provided oral and written informed consent before enrollment.

Study design

This was an 18-day, randomized, double-blind controlled comparative study. Four uniform circular wounds, each 5 mm in diameter, were made to the level of the dermis on the nondominant volar forearm of each subject, using an erbium/carbon dioxide (CO_2) laser after subcutaneous infiltration of lidocaine 1%. The laser settings were two passes of 5 W CO_2, followed by 1.7 J/cm^2 of erbium.

Subjects applied AHO, Poly/Bac/Neo, or Poly/Bac to each of 3 wound sites according to a preassigned randomization scheme, leaving one site as an untreated control. Wounds were covered with a nonstick gauze and a compression wrap. Wounds were cleaned once daily using a cleanser, and treatments were applied 3 times per day for 18 days. Wounds were covered until day 7 postwounding.

Treatments

AHO is composed of petrolatum (41%), mineral oil, ceresin, lanolin alcohol, panthenol, glycerin, and bisabolol. Poly/Bac/Neo ointment contains polymyxin B sulfate (5000 U/g), bacitracin zinc (400 U/g), and neomycin (3.5 mg/g) in a vehicle consisting of cocoa butter, cottonseed oil, olive oil, sodium pyruvate, tocopheryl acetate, and white petrolatum. Poly/Bac ointment contains bacitracin zinc (500 U/g) and polymyxin B sulfate (10,000 U/g) in a white petrolatum vehicle.

Evaluations

Clinical grading of each site was carried out for the parameters erythema, edema, epithelial confluence, crusting, and scabbing, using a 5-point analog scale, before wounding and at days 1, 4, 7, 11, 14, and 18 after wounding. The grading scales were erythema and edema: 0 = none/absent, 1 = mild, 2 = moderate, 3 = marked, 4 = severe; and epithelial confluence, crusting, and scabbing: 0 = none, 1 = slight (up to 30%), 2 = moderate (31%-60%), 3 = extensive (61%-90%), 4 = almost complete or complete (91%-100%). In addition, general wound appearance was evaluated by the investigator, where 0 = poor, 1 = fair, 2 = good, 3 = very good, 4 = excellent.

Subjective grading of the irritation parameters burning, stinging, itching, tightness, tingling, and pain were assessed for each site by the participant before wounding and on days 1, 4, 7, 11, 14, and 18 postwounding. The grade scale used for subjective irritation was 0 = none, 1 = mild, 2 = moderate, 3 = marked, 4 = severe. Subjects were also asked to rank the 4 sites based on appearance each day, where 1 = best appearance and 4 = worst appearance.

Transepidermal water loss (TEWL) was measured before wounding and on days 4, 7, 11, 14, and 18 after wounding. A single DermaLab (Cortex Technologies, Hadsund, Denmark) measurement was performed at each test site. A probe placed on the surface of the skin sampled the relative humidity at two points above the surface, allowing the rate of water loss to be calculated from the measured humidity gradient. Each TEWL measurement was taken over 60 seconds during which there was a 40-second site stabilization followed by 20 seconds where TEWL was captured. A single photograph was taken of each subject's forearm immediately after wounding and on days 1, 4, 7, 11, 14, and 18 using a Nikon D300 SLR digital camera (Nikon, Melville, NY).

Table I. Participant demographics (N = 20)

	n (%)
Gender	
Male	7 (35)
Female	13 (65)
Age range, y (mean)	25.6-49.2 (36.9)
Race	
Caucasian	17 (85)
Hispanic	2 (10)
Mixed (Caucasian/Asian)	1 (5)

Statistical analysis

Statistical differences between test sites for clinical parameters or time points were determined using analysis of variance with Fisher least significant difference. Paired comparisons determined significant changes from baseline for grading parameters.

RESULTS

All enrolled subjects (N = 20) completed the study with no attrition. The average age of participants was 37 years (Table I).

The clinical grading scores showed significant improvements in erythema, edema, and epithelial confluence after AHO treatment compared with Poly/Bac/Neo and Poly/Bac ($P \leq .007$) (Fig 1, *A* to *C*, and Table II). The untreated site and the site treated with AHO showed significantly less erythema than the sites treated with Poly/Bac/Neo and Poly/Bac on day 7 ($P < .0001$). AHO showed significantly less erythema than all of the other sites on days 11, 14, and 18 ($P \leq .007$) (Fig 1, *A*). The AHO-treated sites showed significantly less edema than the other sites on days 4 and 7 ($P \leq .007$) (Fig 1, *B*). The mean epithelial

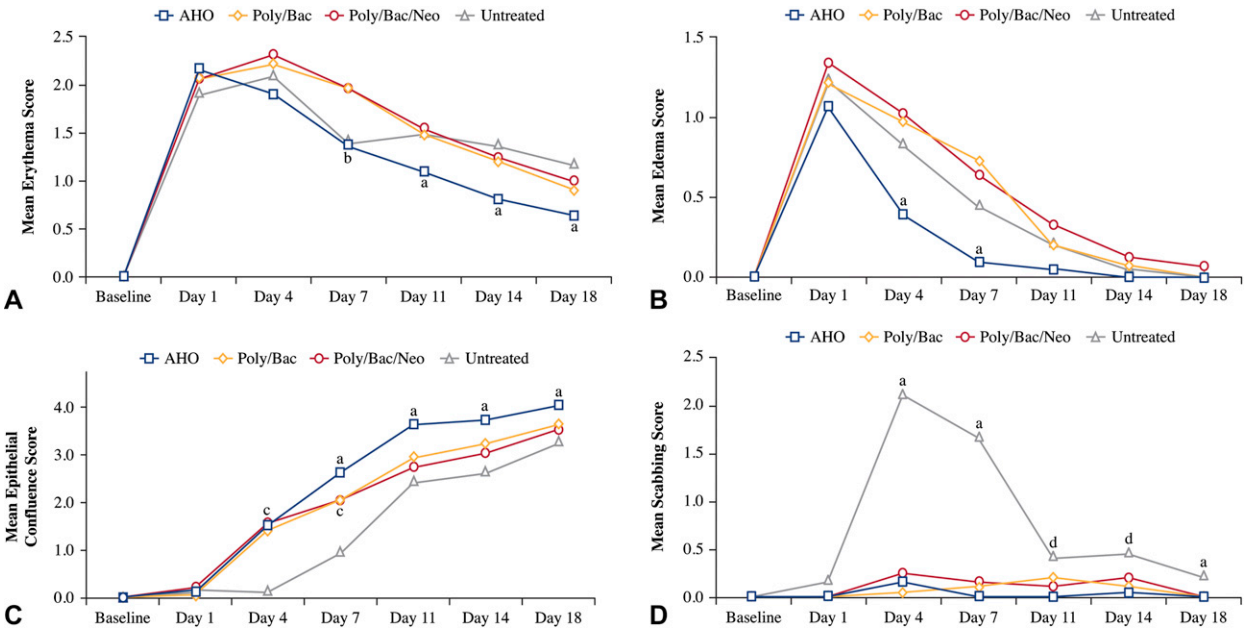

Fig 1. Mean clinical grading scores of wound sites treated with AHO, Poly/Bac, Poly/Bac/Neo, and untreated site. **A,** Erythema. **B,** Edema. **C,** Epithelial confluence. **D,** Scabbing. Erythema and edema grading scale: 0 = none, 1 = mild, 2 = moderate, 3 = marked, 4 = severe. Epithelial confluence grading scale: 0 = none, 1 = slight, 2 = moderate, 3 = extensive, 4 = complete or almost complete. Scabbing grading scale: 0 = none, 1 = slight, 2 = moderate, 3 = extensive, 4 = complete or almost complete. *P* values significantly different from: all other treatments[a]; Poly/Bac and Poly/Bac/Neo[b]; untreated site score[c]; and AHO.[d]

confluence was significantly higher for all 3 treatment groups compared with the untreated site on day 4 ($P < .0001$). Epithelial confluence was significantly higher for AHO compared with other sites on days 7 to 18 ($P \leq .0007$) (Fig 1, *C*). Poly/Bac/Neo and Poly/Bac treatment resulted in significantly higher epithelial confluence than the untreated sites on day 7 ($P < .0001$), and Poly/Bac was significantly higher than the untreated sites on days 14 and 18 ($P \leq .0007$). Scabbing was significantly greater in the untreated wounds than in the treated wounds for days 4, 7, and 18 ($P \leq .0415$) (Fig 1, *D*). Scabbing in the untreated wounds was significantly greater compared with AHO and Poly/Bac/Neo ($P = .034$) on day 11, and compared with AHO and Poly/Bac ($P = .0236$) on day 14. No statistical differences were observed between Poly/Bac/Neo and Poly/Bac for any clinical parameters.

The average change in TEWL was significantly less with AHO compared with the other treatments ($P = .0006$) between baseline and day 4, indicating a greater recovery of the skin barrier. Mean TEWL values were similar between groups at later time points (Fig 2).

The investigator grading of general wound appearance showed significantly higher scores for all of the treated wounds compared with the untreated wounds on day 4 ($P = .0003$) (Fig 3 and Table II). The AHO-treated wounds had significantly higher wound appearance scores on days 7, 11, 14, and 18 ($P \leq .0008$) compared with the Poly/Bac/Neo, Poly/Bac, and control sites. The Poly/Bac sites had significantly higher scores than the untreated sites on days 7 and 11 ($P < .0001$), whereas the Poly/Bac/Neo sites had significantly higher scores than the untreated sites on day 7 ($P < .0001$). Fig 4 shows the progression of wound healing over time for two study participants. Here, the scabbing on days 4 and 7 in the untreated wounds can be clearly seen, particularly in subject 2 (Fig 4, *B*).

Subject daily ranking of the 4 test sites based on wound appearance resulted in mean scores of AHO 1.53 (best), Poly/Bac 2.37, Poly/Bac/Neo 2.49, and the untreated site 3.61 (worst). AHO was statistically superior to the other treatments for the subject ranking.

The incidence of burning, stinging, itching, tightness, tingling, and pain were minimal during this study. No other adverse events were reported by the subjects, and there were no incidences of infection or allergic contact dermatitis for any of the test products or in the control sites.

Table II. Comparative analysis of clinical grading

Clinical parameter	Day	Mean clinical grading score: AHO	Poly/Bac	Poly/Bac/Neo	Untreated wound	Overall *P* value	Statistical comparisons between treatments: AHO vs Poly/Bac	AHO vs Poly/Bac/Neo	AHO vs untreated	Poly/Bac vs untreated	Poly/Bac/Neo vs untreated
Erythema	7	1.35	1.95	1.95	1.38	<.0001	*	*	-	*	*
	11	1.08	1.48	1.53	1.48	.007	*	*	*	-	-
	14	0.80	1.20	1.23	1.35	.0012	*	*	*	-	-
	18	0.63	0.90	0.98	1.15	.0007	*	*	*	-	-
Edema	4	0.40	0.98	1.03	0.83	.007	*	*	*	-	-
	7	0.10	0.73	0.65	0.45	.0009	*	*	*	-	-
Epithelial confluence	4	1.50	1.40	1.55	0.10	<.0001	-	-	*	*	*
	7	2.60	2.05	2.05	0.93	<.0001	*	*	*	*	*
	11	3.60	2.90	2.70	2.38	<.0001	*	*	*	-	-
	14	3.70	3.20	3.00	2.58	.0001	*	*	*	*	-
	18	4.00	3.60	3.50	3.20	.0007	*	*	*	*	-
Scabbing	4	0.15	0.05	0.25	2.10	<.0001	-	-	*	*	*
	7	0.00	0.10	0.15	1.65	<.0001	-	-	*	*	*
	11	0.00	0.20	0.10	0.40	.034	-	-	*	-	*
	14	0.05	0.10	0.20	0.45	.0236	-	-	*	*	-
	18	0.00	0.00	0.00	0.20	.0415	-	-	*	*	*
General wound appearance	4	1.78	1.63	1.53	1.05	.0003	-	-	*	*	*
	7	2.50	1.95	1.95	1.55	<.0001	*	*	*	*	*
	11	3.25	2.55	2.45	1.95	<.0001	*	*	*	*	-
	14	3.40	2.75	2.60	2.20	.0008	*	*	*	-	-
	18	3.75	3.15	2.90	2.70	.0003	*	*	*	-	-

Only parameters and time points that showed statistical differences between treatments are shown. Overall *P* value shows statistical significance between test materials and untreated site.

*Statistical difference between treatments. No statistical differences were observed between Poly/Bac/Neo and Poly/Bac for any parameter or time point.

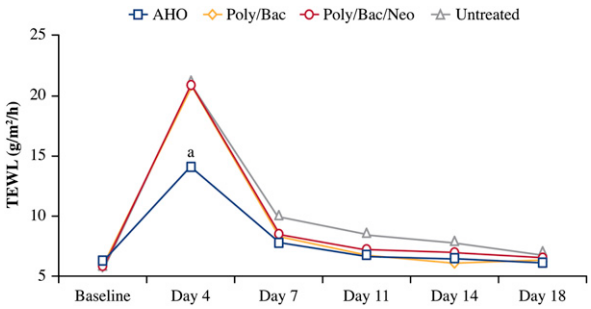

Fig 2. Transepidermal water loss (*TEWL*). Instrumental analysis of water loss caused by damage of stratum corneum in g/m^2/h. [a]*P* value significantly different from all other treatments (*P* = .0006).

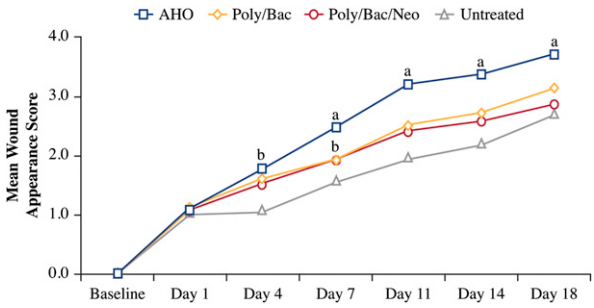

Fig 3. Investigator grading of general wound appearance (mean scores). Wound appearance grading scale: 0 = poor, 1 = fair, 2 = good, 3 = very good, 4 = excellent. *P* values significantly different from: all other treatments[a]; and untreated site score.[b]

DISCUSSION

The results of this study demonstrate that AHO provides fast healing in several wound healing parameters compared with the two tested antibiotic ointments. AHO showed significant improvements in erythema (days 7-18), edema (days 4 and 7), epithelial confluence (days 7-18), and general wound appearance (days 7-18) compared with both Poly/Bac/Neo and Poly/Bac. Although Poly/Bac/Neo and Poly/Bac treatment resulted in some statistical improvements in epithelial confluence, scabbing, and overall wound appearance compared with the untreated sites, they exhibited no statistical improvements in edema or erythema at any time point compared with the untreated control, and they were consistently graded lower than AHO for all parameters. In addition, the overall wound appearance of the sites treated with AHO were graded as superior to those treated with either of the antibiotic-based ointments by both the investigators and the study participants. Poly/Bac

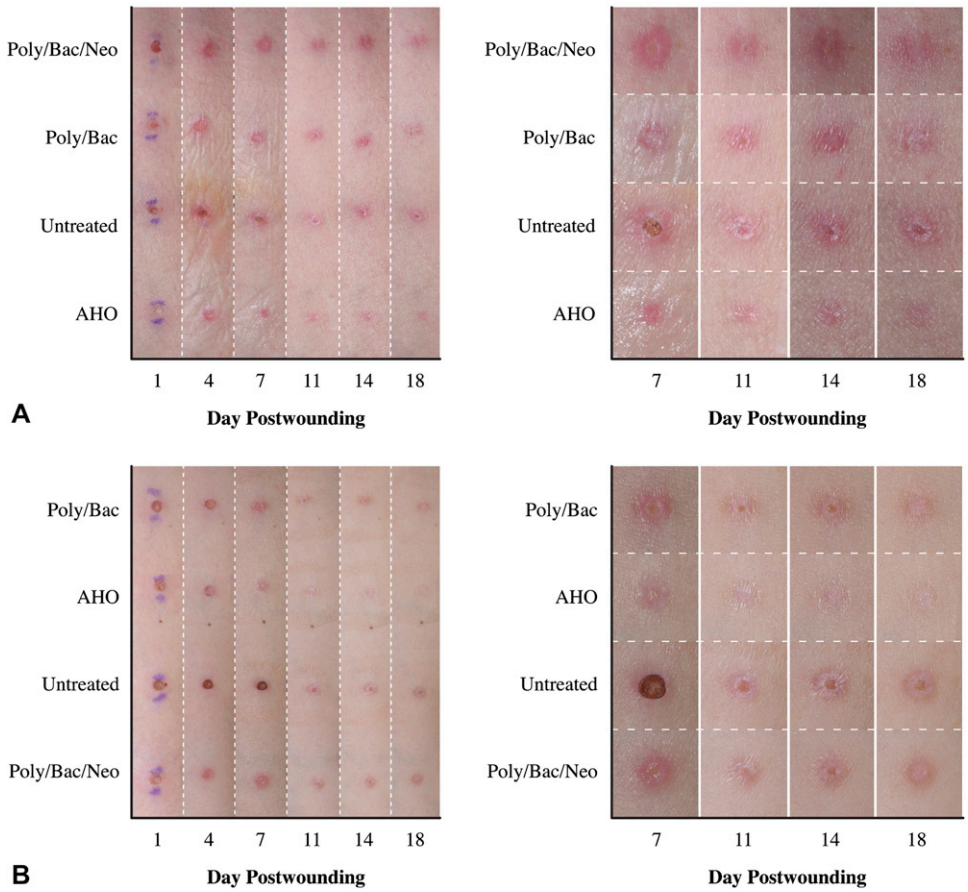

Fig 4. Progression of wound healing in individual subjects from day 1 to 18. Magnified results shown for day 7 to 18. Subjects 1 (**A**) and 2 (**B**).

was ranked as the second best in overall wound appearance, followed by Poly/Bac/Neo and the untreated site.

The TEWL results indicated that AHO caused a rapid improvement in skin barrier function, which was not seen with Poly/Bac/Neo or Poly/Bac. TEWL measurement is a validated method designed to determine the health and function of the stratum corneum. It is used as a sensitive measure of damage to the barrier function of the stratum corneum and for monitoring the repair of such damage.[10] The skin barrier is central to healthy skin. When the barrier is compromised, the risk of infection is increased, causing many physicians to recommend the use of prophylactic antibiotic ointments. This study demonstrated that AHO actually enhanced barrier repair relative to the other ointments, further reducing the need for topical antibiotics.

AHO is an antibiotic-free, petrolatum-based ointment that also contains humectants, skin conditioners, and natural barrier lipids, allowing it to facilitate wound healing. The formulation creates a semiocclusive environment that allows the exchange of oxygen necessary for wound healing. The formulation is able to absorb more than 3 times its weight in aqueous solutions, which helps to absorb the wound exudates. In clinical practice, AHO is often used for the treatment of superficial wounds and injuries and for standard postoperative care for laser procedures, such as CO_2 laser resurfacing, and fractional ablative resurfacing.[11-13]

In contrast to AHO, Poly/Bac contains antibiotic actives in a white petrolatum vehicle. Poly/Bac/Neo contains several ingredients in addition to a white petrolatum base and antibiotics. The antibiotic components of these ointments have been shown to have the potential to cause allergic contact dermatitis. In this study, no incidence of allergic contact dermatitis was reported for any of the tested ointments. This was not unexpected, given the small sample size of the study and that participants with known allergies to skin care products or antibiotics were excluded from the study.

More importantly, this study revealed no difference in infection between AHO (a petrolatum-containing ointment) and antibiotic ointments, a

finding that agrees with previous studies,[8,9] and suggests that prophylactic antibiotics are not necessary for the prevention of infections in minor clinical wounds. Furthermore, overuse of antibiotics has the potential to cause drug resistance, resulting in the need for more powerful antimicrobials. The results from this study indicate that the posttreatment care of minor clinical wounds may be one area where antibiotic use can be reduced with no detrimental outcomes.

The erbium/CO_2 laser is a tool that ablates the epidermis precisely and reproducibly.[14-17] Thus, the laser wounding model used in this study enabled reproducible, uniform wounds to be created that were standardized in both diameter and depth. Using such a model maximizes the ability to detect small differences between treatments that might otherwise be indistinguishable. In clinical studies, wounds have many variables in, for instance, size and depth, which may limit the ability to detect differences between treatments. The wounds created using the laser wounding model are similar to the wounds that are created when performing curettage, electrodessication, and shave removal of lesions in the dermatologist's office.

This was a small sample pilot study. Typically, model studies do not need a large number of participants because there is less variation within the population. In this study, in particular, the individual wounds did not vary because of the reproducibility of the laser wounding procedure. In addition, each person received all treatments and served as their own control. With such uniformity, a sample size of 20 would be expected to show differences between healing parameters as was seen here with several statistical differences being detected between treatments. A potential limitation of this study is that only two antibiotic combination preparations were investigated. It is possible that other antibiotic ointments may produce better healing than either Poly/Bac/Neo or Poly/Bac. Nevertheless, the two combinations tested here are the most commonly used topical wound care products, and therefore these results should be applicable to current practices. Finally, the fact that this study used a laser to create wounds that ablate the epidermis should be interpreted accordingly when relating findings to real-world wounds.

CONCLUSION

This study demonstrated that AHO exhibited superior wound healing compared with antibiotic-based ointments. No infections were seen for either the antibiotic-based treatments or AHO. Wound healing was faster with AHO, with less erythema, edema, and scabbing; better epithelial confluence; and superior overall wound appearance. These results suggest that prophylactic antibiotics may not be necessary for the prevention of infection in clean superficial wounds created in daily dermatologic practice.

The authors thank Jennifer DiLembo, BA, CCRC, for her contributions to the study; Paul Kavanaugh, MS, for statistical analyses; and Jodie Macoun, PhD, from Evince Communications for writing assistance and editorial support.

REFERENCES

1. Fleischer AB Jr, Feldman SR, White RE, Leshin B, Byington R. Procedures for skin diseases performed by physicians in 1993 and 1994: analysis of data from the National Ambulatory Medical Care Survey. J Am Acad Dermatol 1997;37:719-24.
2. Neville JA, Housman TS, Letsinger JA, Fleischer AB Jr, Feldman SR, Williford PM. Increase in procedures performed at dermatology office visits from 1995 to 2001. Dermatol Surg 2005;31:160-2.
3. Doughty D. Dressings and more: guidelines for topical wound management. Nurs Clin North Am 2005;40:217-31.
4. Sheth VM, Weitzul S. Postoperative topical antimicrobial use. Dermatitis 2008;19:181-9.
5. Spann CT, Taylor SC, Weinberg JM. Topical antimicrobial agents in dermatology. Dis Mon 2004;50:407-21.
6. Ross JI, Snelling AM, Carnegie E, Coates P, Cunliffe WJ, Bettoli V, et al. Antibiotic-resistant acne: lessons from Europe. Br J Dermatol 2003;148:467-78.
7. Gehrig KA, Warshaw EM. Allergic contact dermatitis to topical antibiotics: epidemiology, responsible allergens, and management. J Am Acad Dermatol 2008;58:1-21.
8. Smack DP, Harrington AC, Dunn C, Howard RS, Szkutnik AJ, Krivda SJ, et al. Infection and allergy incidence in ambulatory surgery patients using white petrolatum vs bacitracin ointment: a randomized controlled trial. JAMA 1996;276:972-7.
9. Campbell RM, Perlis CS, Fisher E, Gloster HM Jr. Gentamicin ointment versus petrolatum for management of auricular wounds. Dermatol Surg 2005;31:664-9.
10. Tupker RA, Pinnagoda J. Measurement of transepidermal water loss by semiopen systems. In: Serup J, Jemec GBE, Grove GL, editors. Handbook of non-invasive methods and the skin. 2nd ed. Boca Raton (FL): Taylor and Francis; 2006. pp. 383-92.
11. Hunzeker CM, Weiss ET, Geronemus RG. Fractionated CO_2 with laser resurfacing: our experience with more than 2000 treatments. Aesthet Surg J 2009;29:317-22.
12. Railan D, Kilmer S. Ablative treatment of photoaging. Dermatol Ther 2005;18:227-41.
13. Rullan PP, Lemon J, Rullan J. The 2-day light peel chemabrasion for deep wrinkles and acne scars: a presentation of face and neck peels. Am J Cosmetic Surg 2004;21:15-26.
14. Rizer RL, Mills OH, Campbell M, Turner MB, Miller DL, Kowcz A. Non-invasive bioengineering techniques used in the assessment of wound healing. Clin Pharmacol Ther 2002;71:13.
15. Rizer RL, Mills OH, Turner MB, Kowcz A, Weber TM. Use of laser wound model coupled with non-invasive bioengineering methods to evaluate the effectiveness of topical wound

healing agents. Presented at: International Society for Bioengineering and the Skin (ISBS); October 24-26, 2002; Baltimore, MD.

16. Rizer RL, Maas-Irslinger R, Mills OH, Turner MB, Kowcz A. Treatment effects on wound healing and amelioration of scar formation. Presented at: Annual Meeting of the American Academy of Dermatology; March 2-7, 2001; Washington, DC.
17. Sigler ML, Kowcz A, Maas-Irslinger R, Mills OH, Hino PD. Novel methodology for assessing wound healing formulations. Presented at: Annual Meeting of the American Academy of Dermatology; February 22-27, 2002; New Orleans, LA.